



Radiology Review Course 2015  
University of Washington

# Arthritis



**Felix S. Chew, MD**  
**University of Washington**

## Disclosures

I have no disclosures.

## Learning Objectives

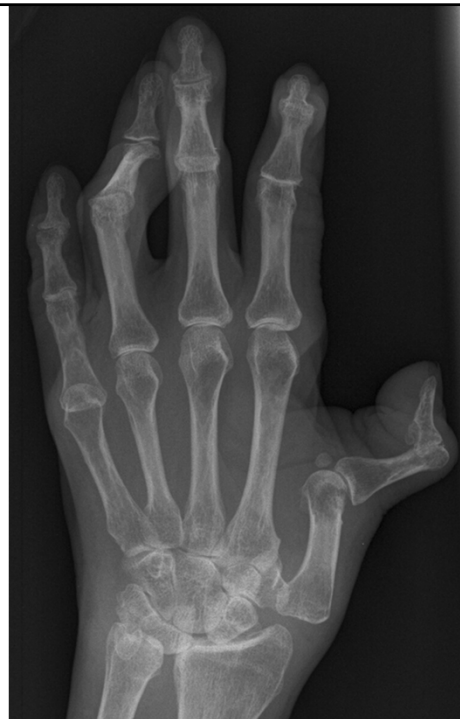**At the conclusion of this activity, participants will be able to:**

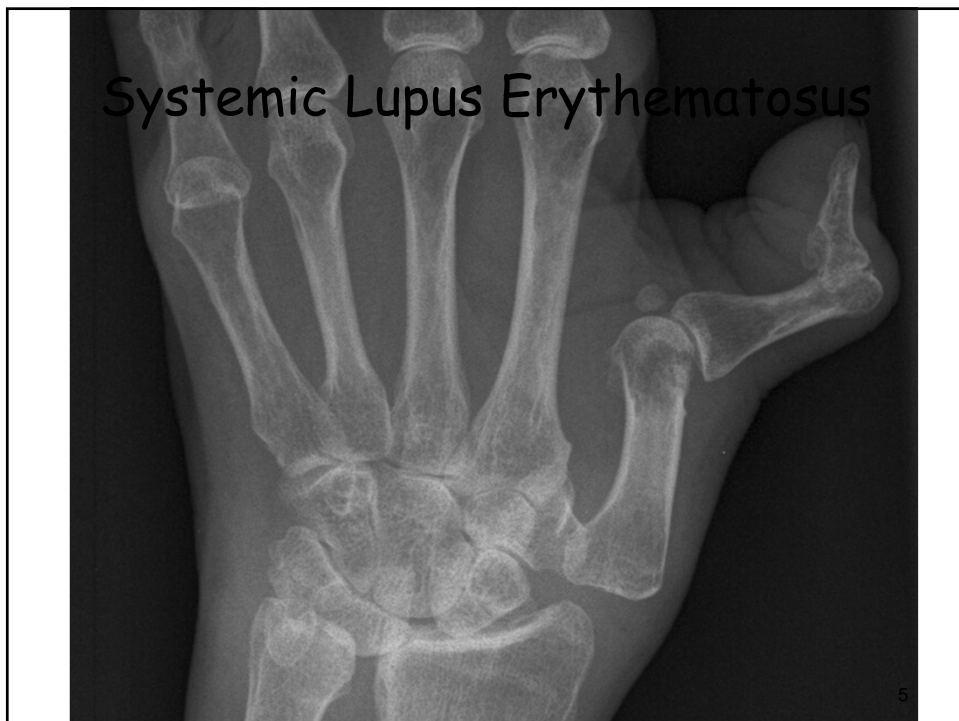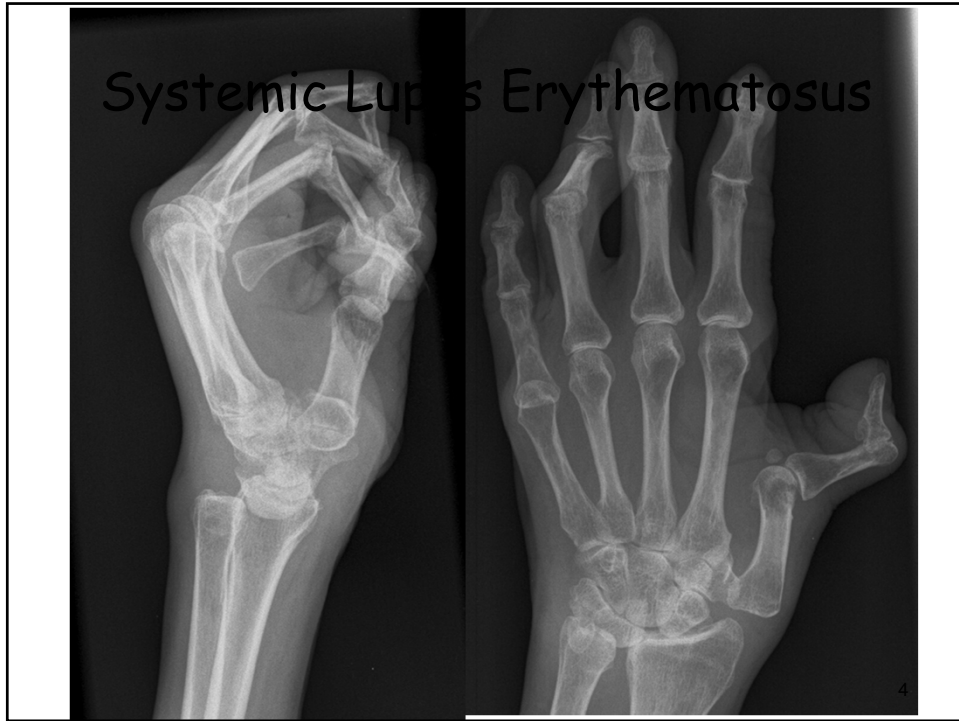- Identify and describe radiologic features of inflammatory arthritis;
- Identify and describe radiologic features of non-inflammatory joint disease.

2

### 1. Best diagnosis?

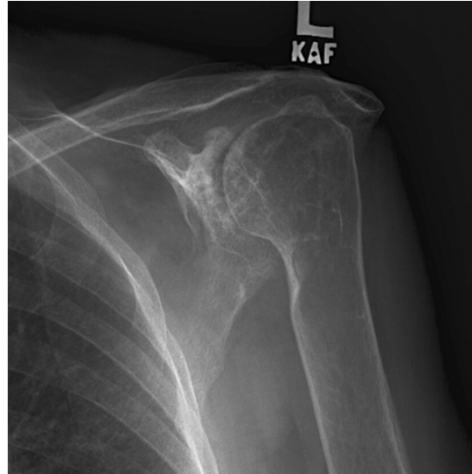- A. Osteoarthritis
- \* B. Systemic lupus erythematosus
- C. Rheumatoid arthritis
- D. Psoriatic arthritis





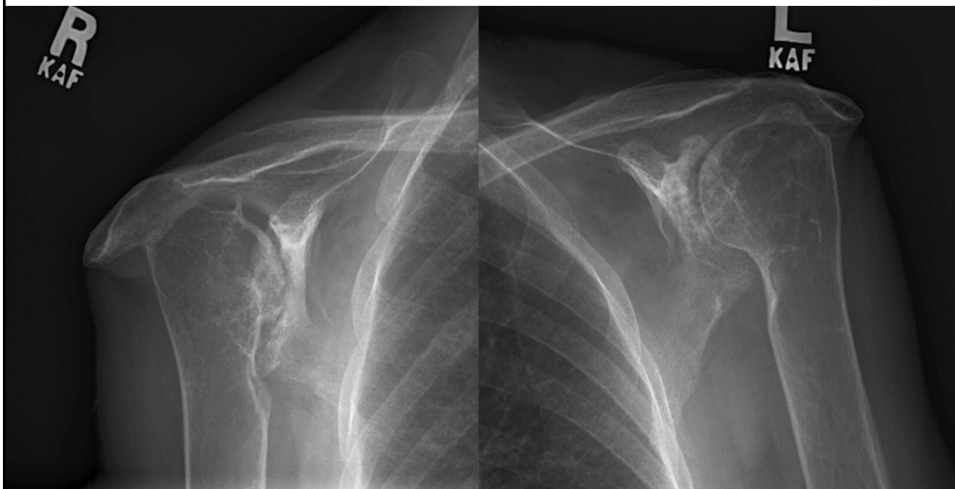
## 2. Best diagnosis?

- A. Pyrophosphate arthropathy
- \* B. Rheumatoid arthritis
- C. Neuropathic osteoarthropathy
- D. Osteoarthritis



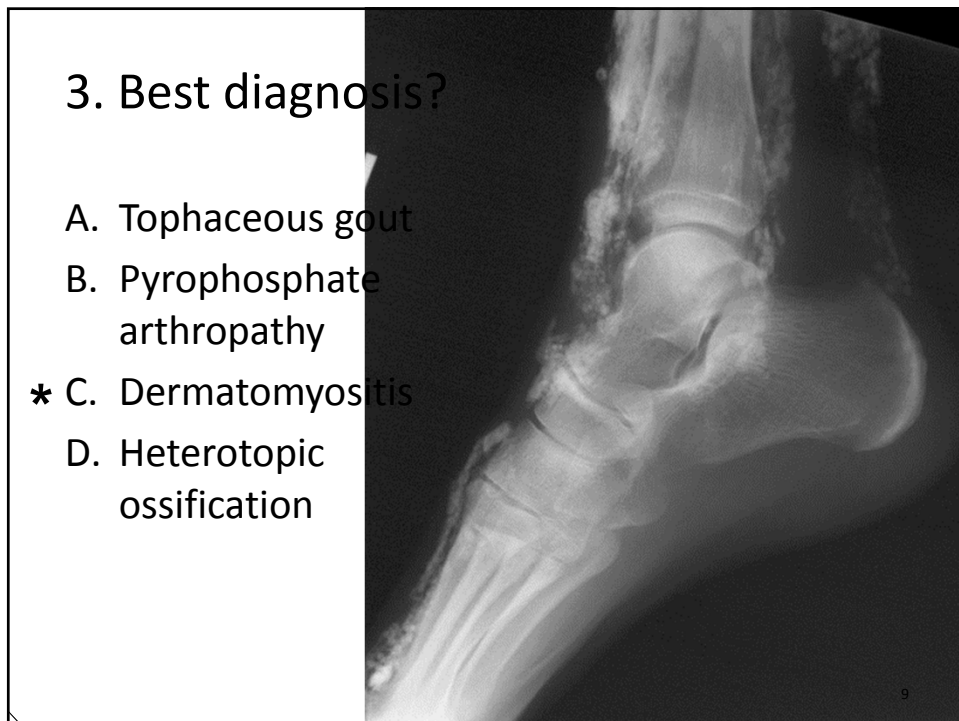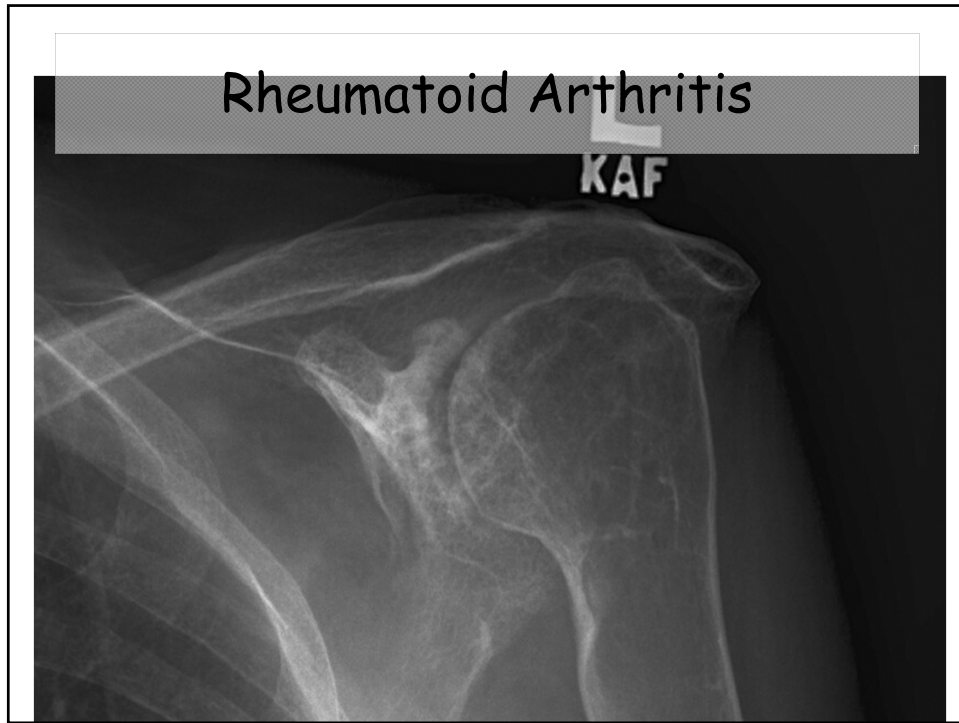
6

## Rheumatoid Arthritis



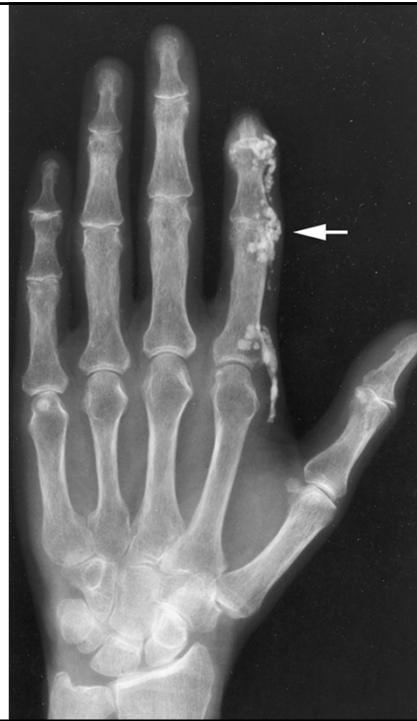7



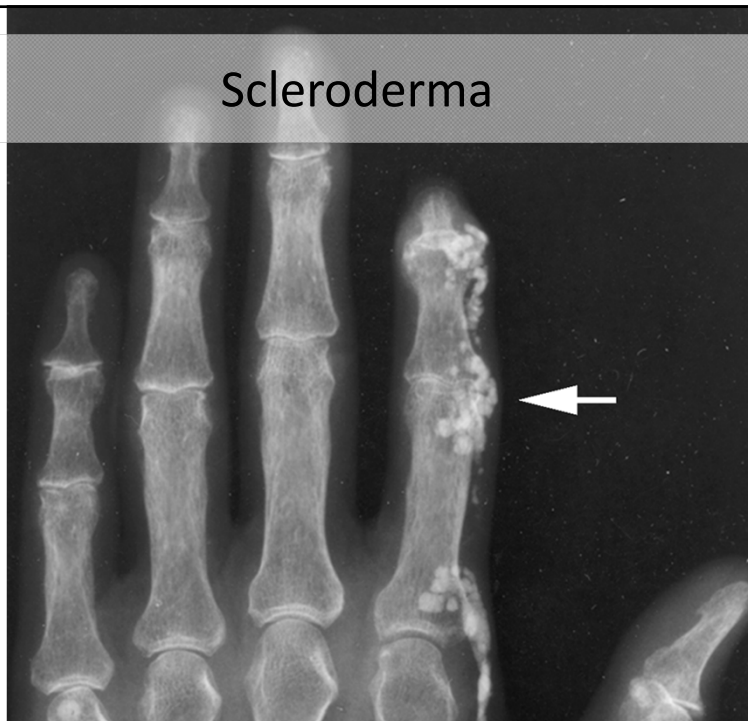

4. Best diagnosis?

- A. Osteoarthritis
- B. Rheumatoid arthritis
- C. Systemic lupus erythematosus
- \* D. Scleroderma

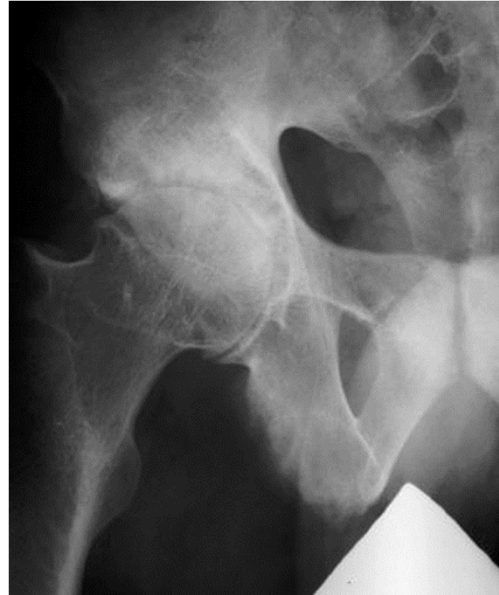


Scleroderma



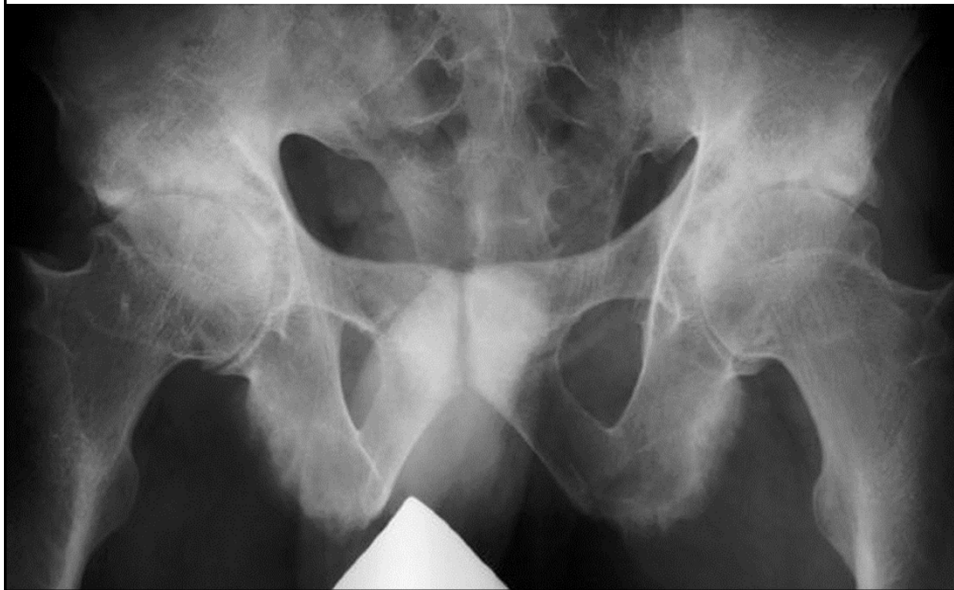
5. Best diagnosis?

- A. Osteoarthritis
- B. Ankylosing spondylitis
- \* C. Rheumatoid arthritis
- D. Psoriatic arthritis

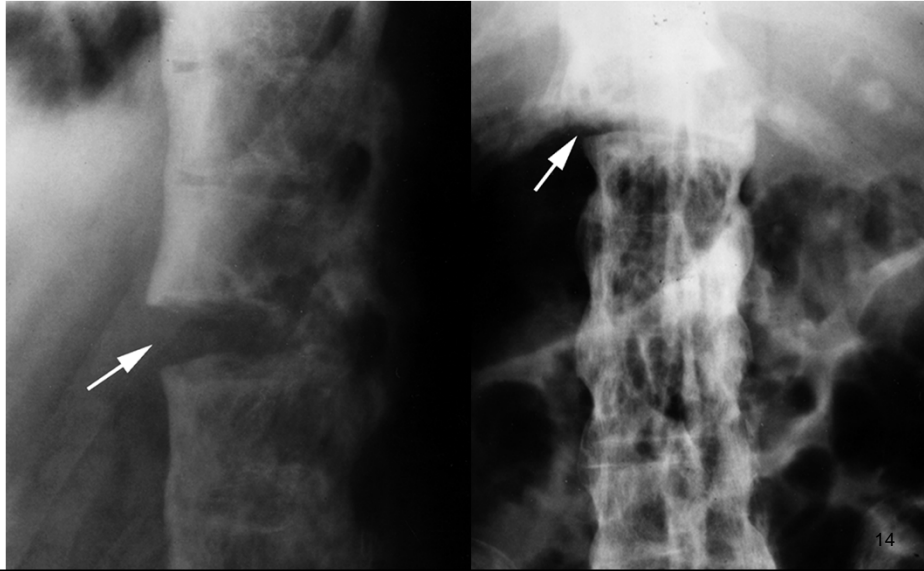


12

## Ankylosing Spondylitis

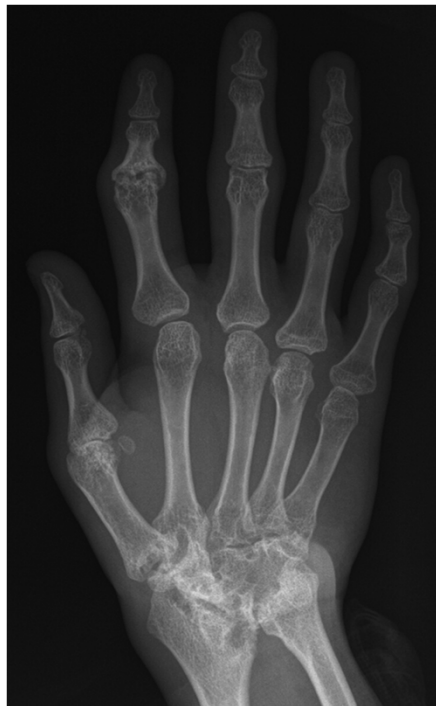

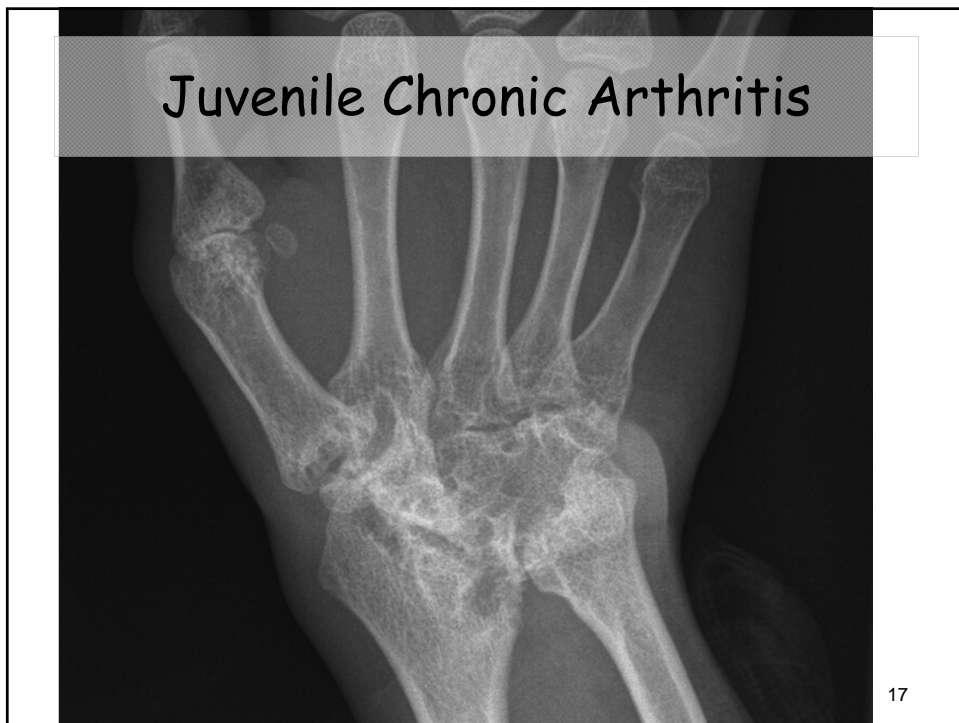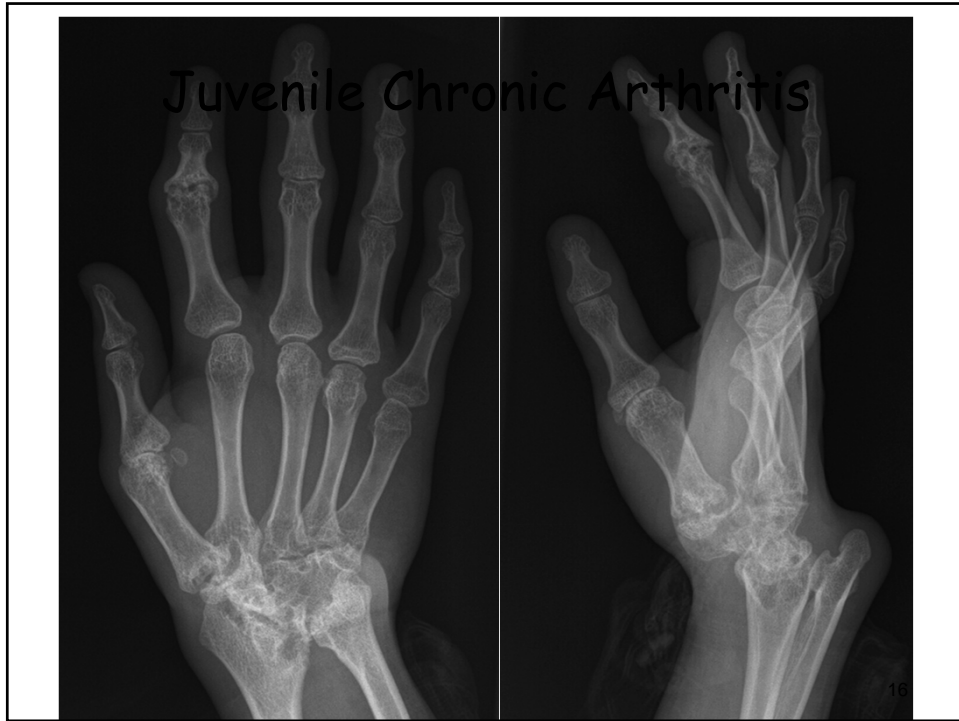## Ankylosing Spondylitis

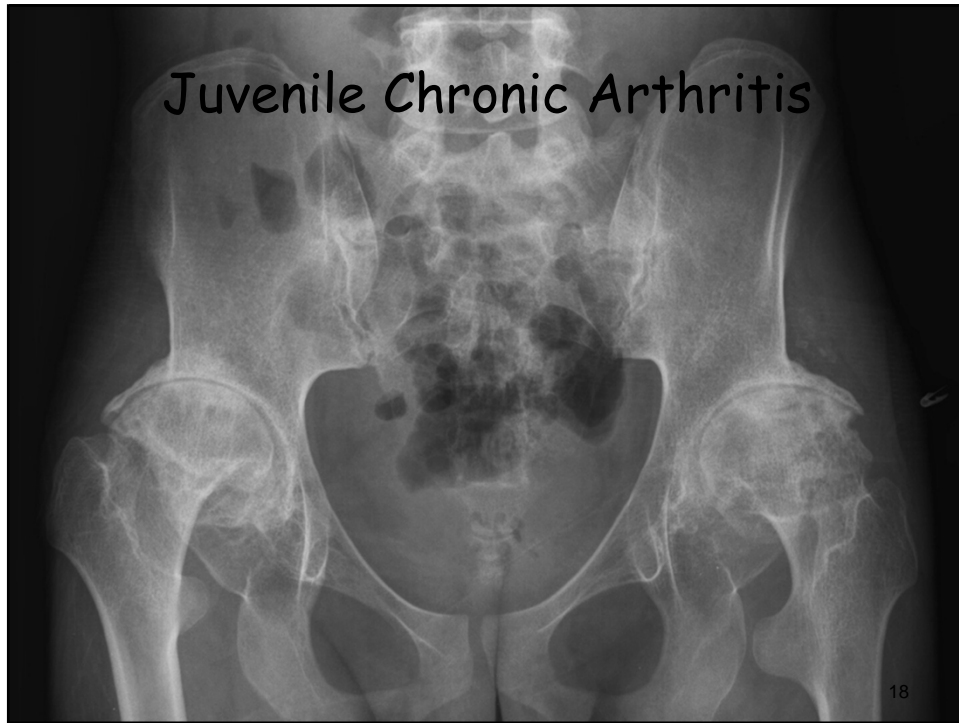


6. Best diagnosis?

- A. Rheumatoid arthritis
- B. Pyrophosphate arthropathy
- \* C. Juvenile chronic arthritis
- D. Osteoarthritis

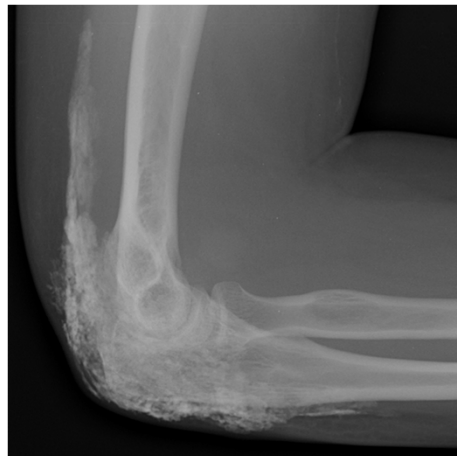



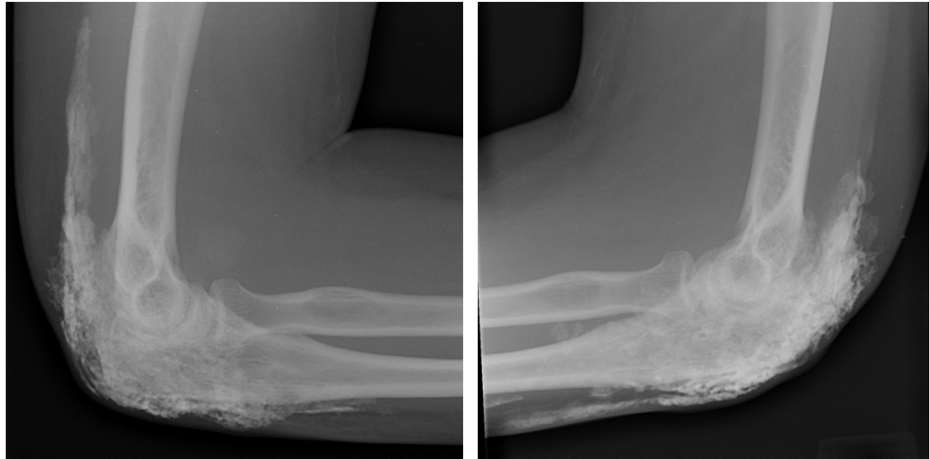


7. Best diagnosis?

- \* A. Dermatomyositis
- B. Scleroderma
- C. Tumoral calcinosis
- D. Heterotopic ossification



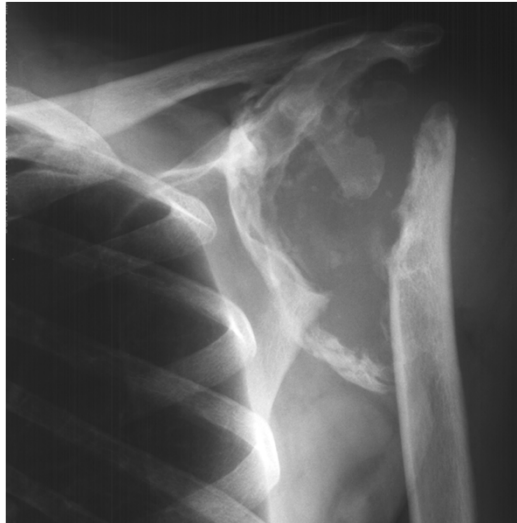## Dermatomyositis



20

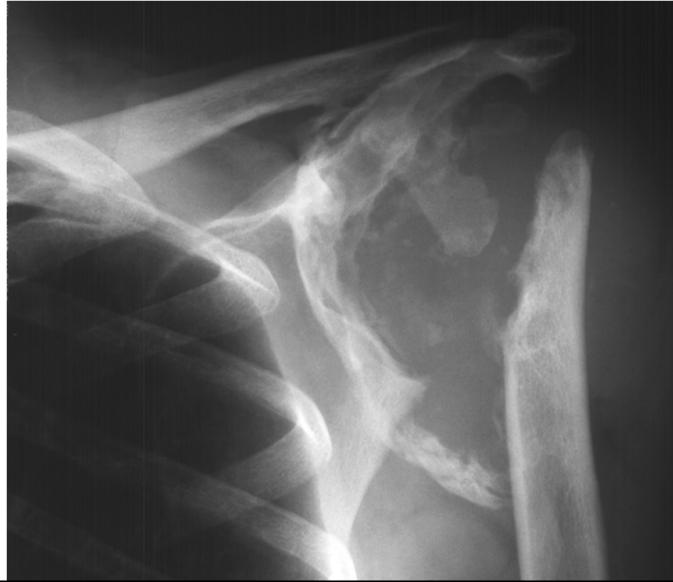### 8. Best diagnosis?

- A. Septic arthritis
- B. Rheumatoid arthritis
- \* C. Neuropathic osteoarthropathy
- D. Osteoarthritis



21

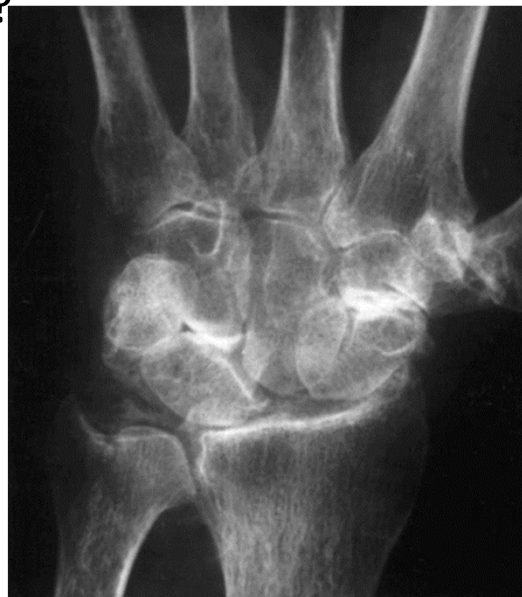## Neuropathic Osteoarthropathy



22

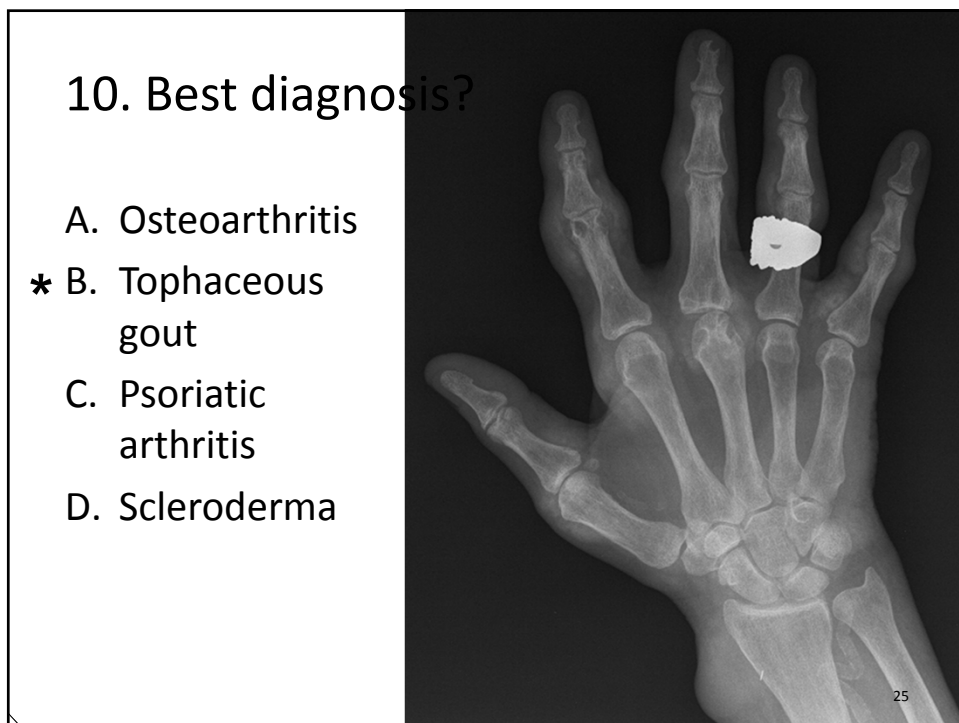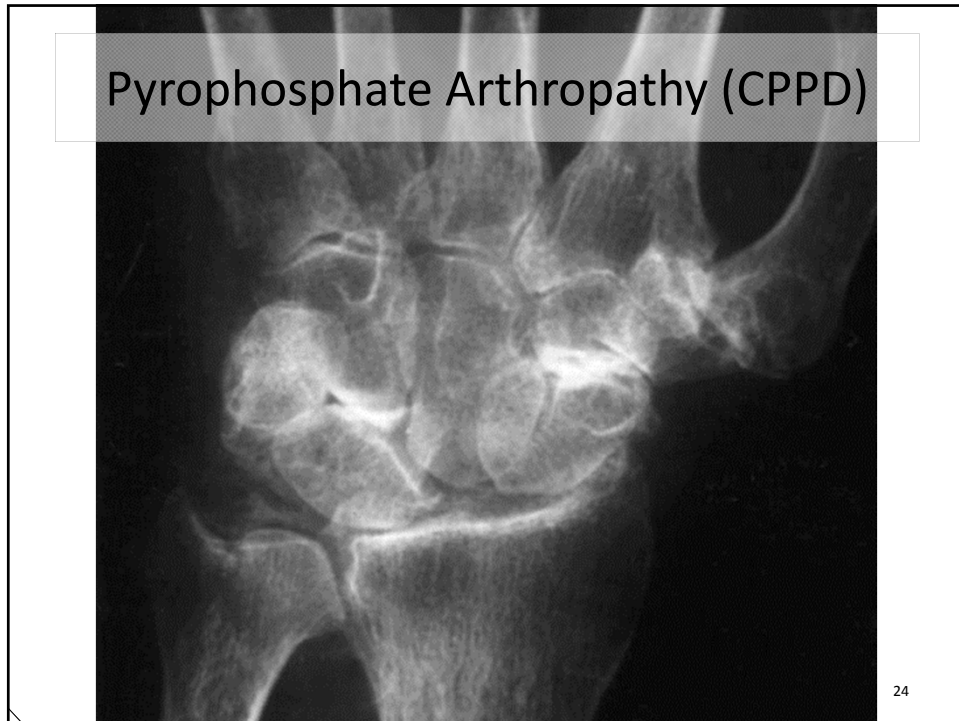
## 9. Best diagnosis?

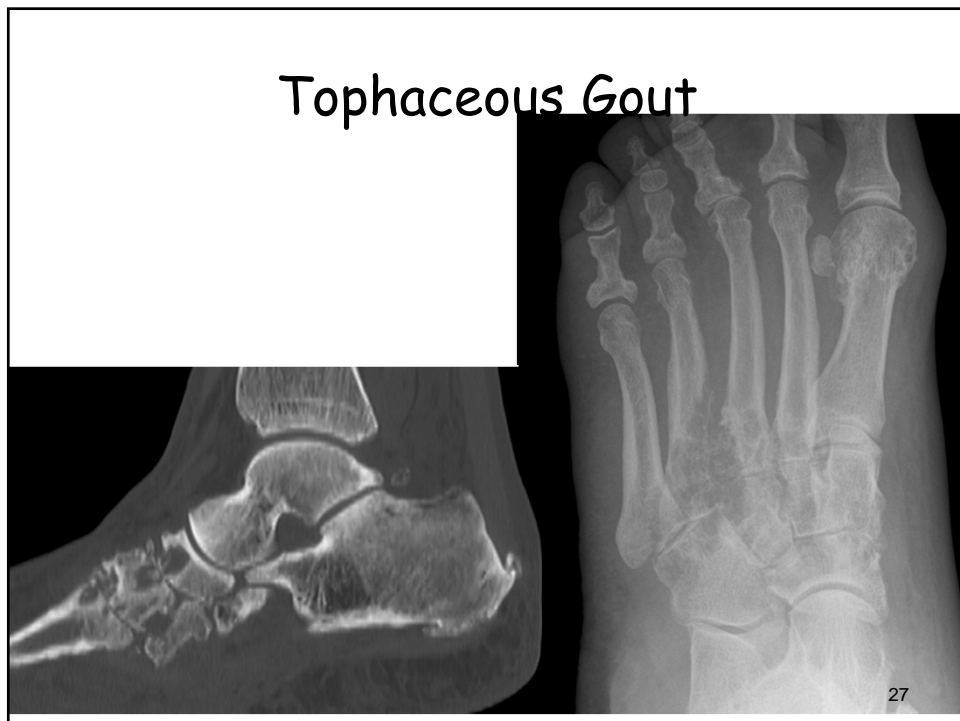
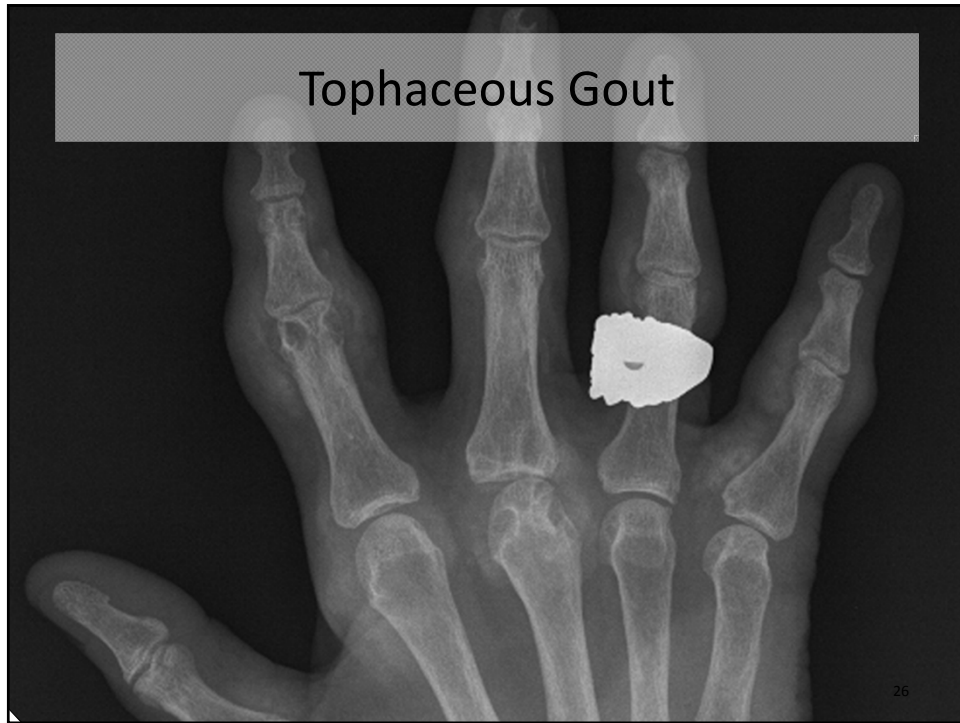
- A. Rheumatoid arthritis
- B. Systemic lupus erythematosus
- C. Osteoarthritis
- \* D. Pyrophosphate arthropathy



23

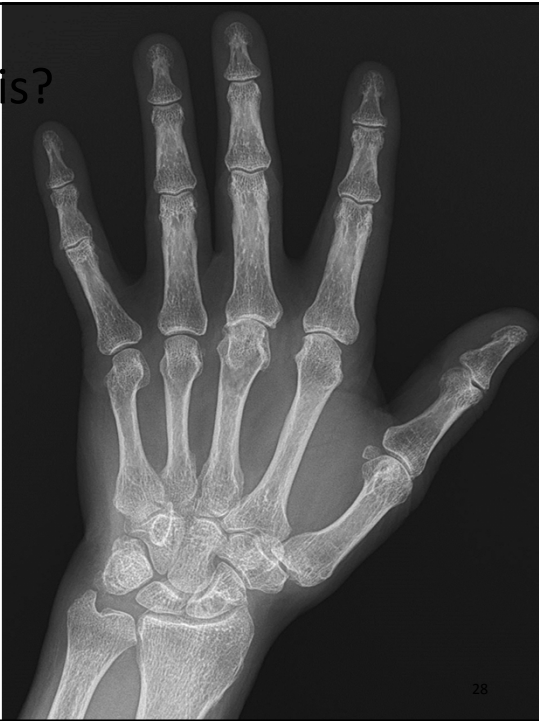




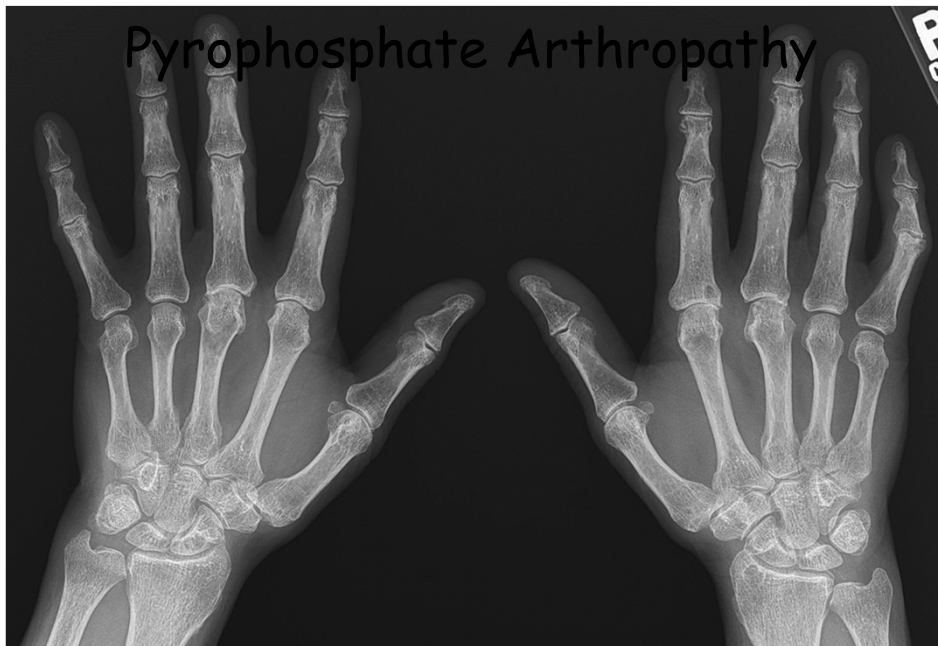
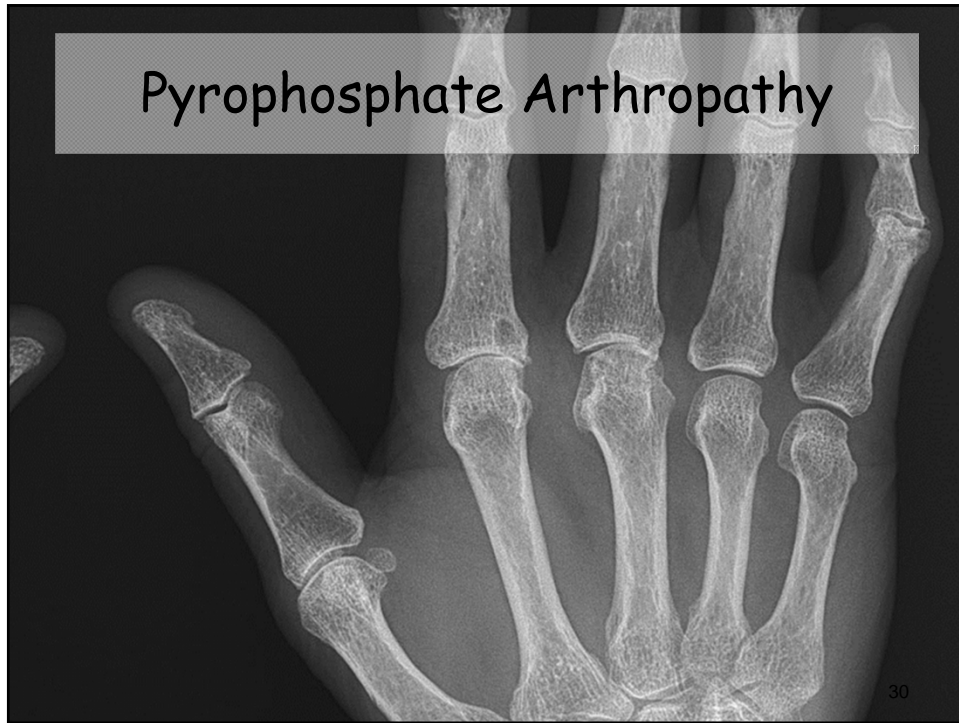11. Best diagnosis?

- A. Erosive osteoarthritis
- B. Rheumatoid arthritis
- \* C. Pyrophosphate arthropathy
- D. Psoriatic arthritis



Pyrophosphate Arthropathy

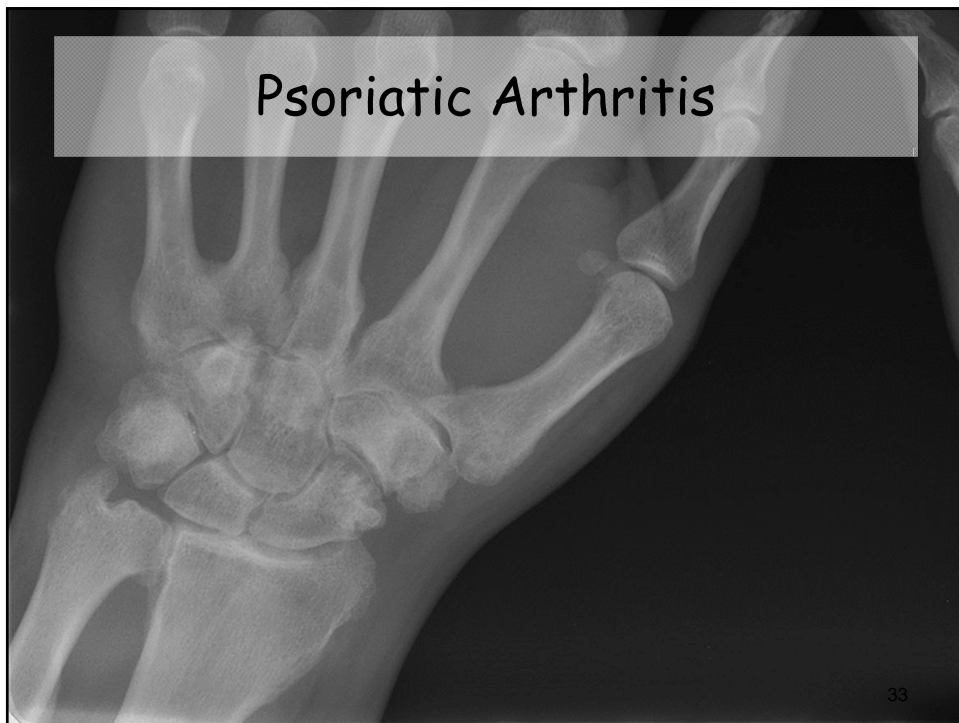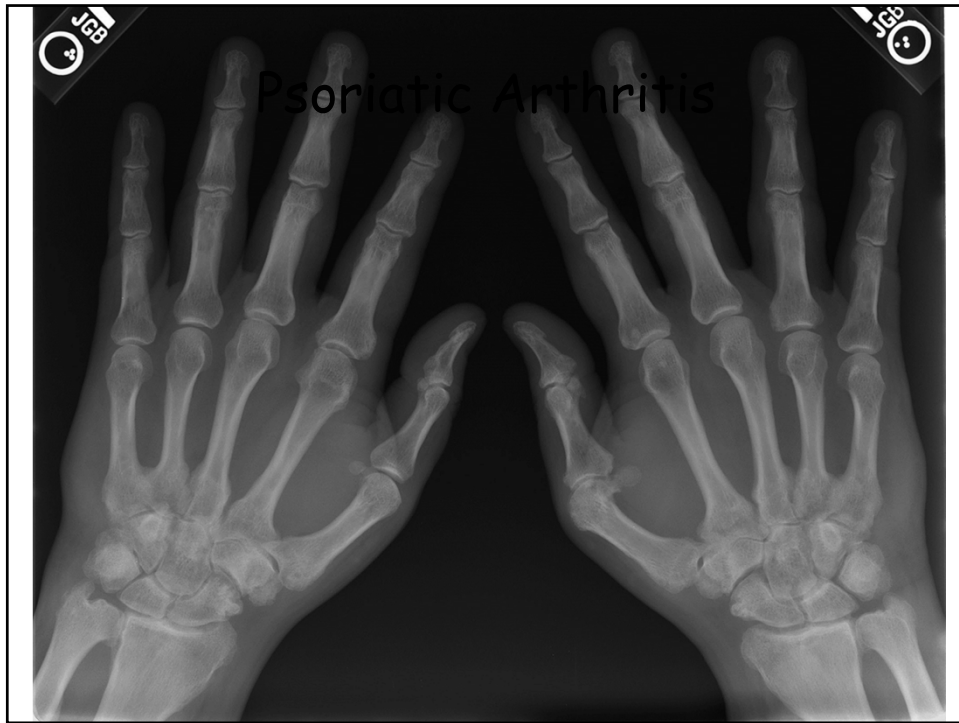




12. Best diagnosis?

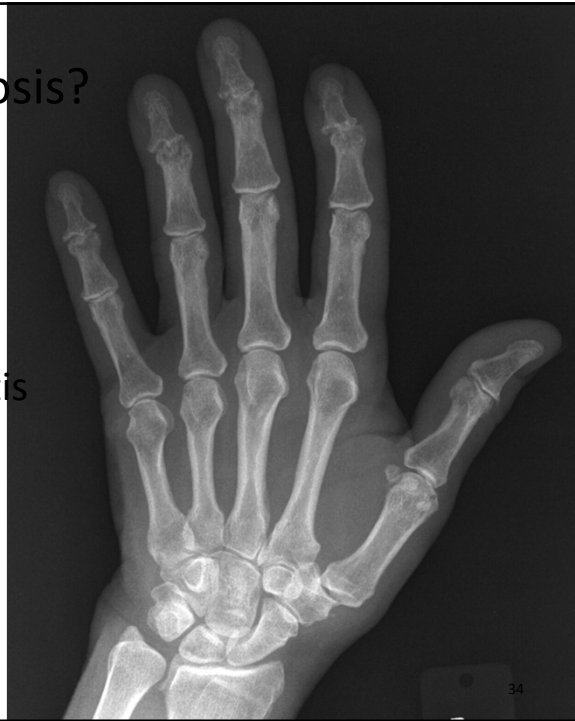- \* A. Psoriatic arthritis
- B. Rheumatoid arthritis
- C. Pyrophosphate arthropathy
- D. Osteoarthritis



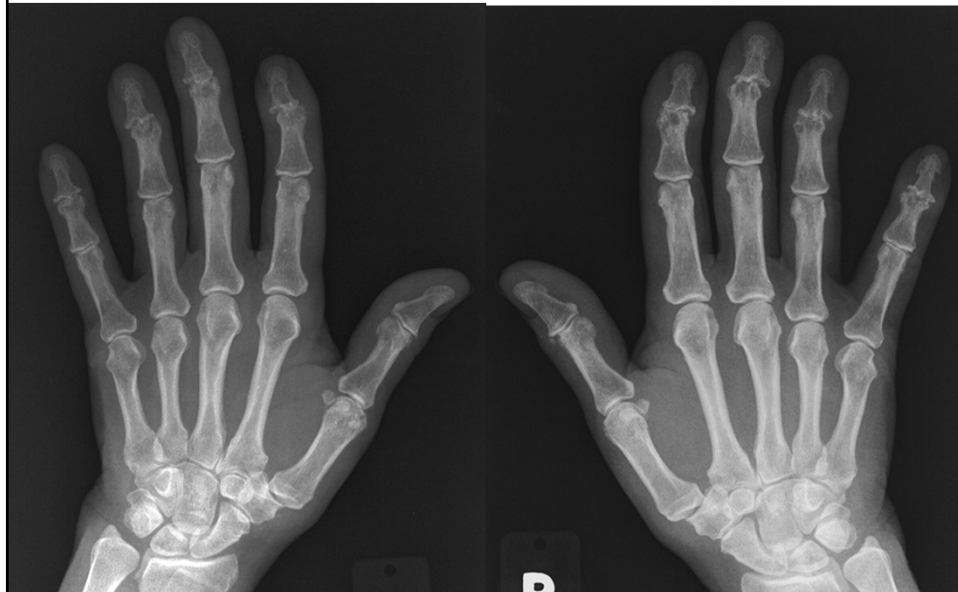

13. Best diagnosis?

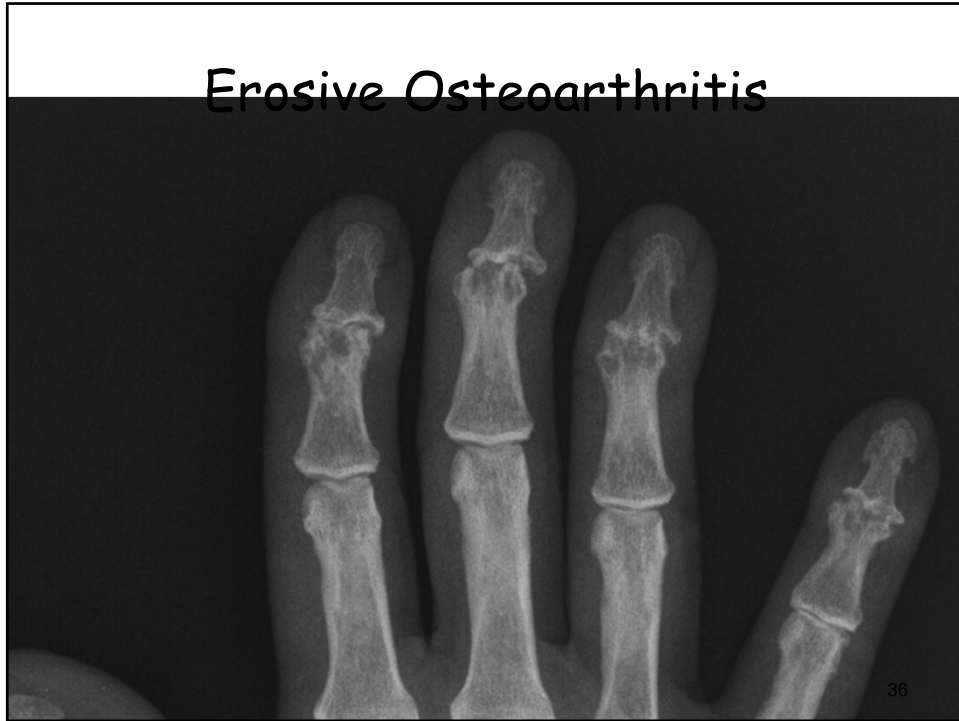- A. Scleroderma
- B. Rheumatoid arthritis
- C. Psoriatic arthritis
- \* D. Erosive osteoarthritis



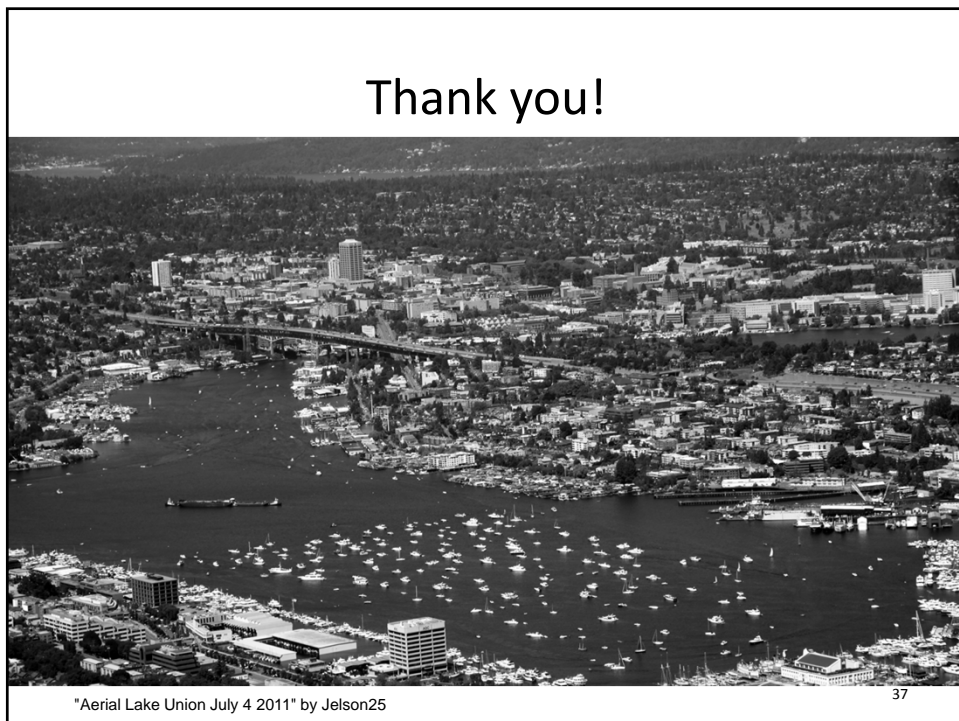
## Erosive Osteoarthritis



## Erosive Osteoarthritis



Thank you!



1. Which condition and radiologic manifestation match most closely?

- A. Osteoarthritis : calcinosis cutis
- B. Scleroderma : erosions
- \* C. Psoriatic arthritis : periostitis
- D. Tophaceous gout : osteophytes

38

2. Which condition and radiologic manifestation match most closely?

- A. Rheumatoid arthritis : osteophytes
- \* B. Systemic lupus erythematosus : alignment deformities
- C. Neuropathic osteoarthropathy : periostitis
- D. Pyrophosphate arthropathy : lumpy bumpy soft tissue swelling

39